

## FASCIA LATA VERSUS SILICONE SLING FRONTALIS SUSPENSION FOR CORRECTION OF CONGENITAL BLEPHAROPTOSIS

Afroz Khan, Obaid Majid, Junaid Wani

Post Graduate Department of Ophthalmology, Government Medical College, Srinagar, J & K, India

Correspondence to: Obaid Majid (obaidmajid@gmail.com)

DOI: 10.5455/ijmsph.2014.180320142

Received Date: 06.03.2014

Accepted Date: 15.05.2014

### ABSTRACT

**Background:** The ideal surgical treatment and age of intervention were controversial in the management of congenital ptosis, however congenital ptosis should be corrected in the early years of childhood, and amblyopia treatment commenced as soon as the diagnosis is established.

**Aims & Objective:** To compare the cosmetic and functional results of frontalis suspension in congenital blepharoptosis using Fascia lata versus Silicone sling.

**Materials and Methods:** In a prospective randomized study, that was conducted at Government Medical College, Srinagar -India from 1st January 2010 to 1st March 2012, thirty patients with age ranging from 5-55 years, with congenital ptosis having levator function of 4 mm or less were randomly divided into two groups: Group I (which included 15 patients who underwent frontalis brow suspension using fascia lata) and Group II (which consisted of 15 patients who underwent frontalis brow suspension using silicone sling). After proper pre-operative assessment Frontalis brow suspension was performed under general / local anaesthesia. Post-operative Cosmetic results, recurrence rates and associated complications were compared between these 2 groups. Final results were taken to be those at 3 months post-operative.

**Results:** All patients had severe ptosis with average preoperative margin to reflex distance (MRD) of  $-0.78 \pm 1.23$  mm. All eyelid in unilateral cases and worst eye in bilateral cases had poor levator function averaging  $3.45 \pm 0.55$  mm and average levator function in better eyelid of bilateral cases was  $4 \pm 0.39$  mm.

Postoperatively in Group I, 14 (93%) out of 15 had satisfactory results based on MRD, among which, 12 (80%) patients showed good improvement in MRD ( $> 3$  mm) and 2(13%) patients had moderate improvement in MRD ( $> 2$  mm  $< 3$  mm). The remaining 1 (7%) of 15 patients had poor MRD ( $< 1.5$  mm). No other complications were noted. In Group II, 11 (73%) out of 15 had satisfactory cosmetic and functional results. These patients exhibited good improvement in MRD ( $>3$  mm). The remaining 4 (27%) of 15 patients showed poor MRD ( $< 1.5$ mm). Post-operative complications in Group II were as follows: 4 (26%) out of 15 patients showed under correction of ptosis, 1 (7%) patient had recurrence of ptosis due to slippage of silicone tube, 1 (7%) patient had granuloma formation, 1 (7%) patient had exposure of silicone sling after four postoperative weeks. Average post-operative MRD with brow up was  $3.55 \pm 0.73$  mm in group I and  $2.95 \pm 0.17$  mm in group II at 3 months after surgery.

**Conclusion:** The established treatment for ptosis with poor levator function is frontalis sling suspension surgery. The upper ptotic lid is attached to the frontalis muscle and the lid is elevated actively on elevating brow. Treatment of severe congenital ptosis with frontalis brow suspension showed significantly good cosmetic and functional results using fascia lata (93%) as compared to silicone tube (73%). Larger prospective controlled trials are required to come to definite conclusion of superiority of any one of two materials.

**Key Words:** Congenital Blepharoptosis; Frontalis Brow Suspension; Fascia Lata; Silicone Sling; Margin to Reflex Distance

### Introduction

Ptosis of the upper eyelid is a condition in which the upper eyelid margin is in an abnormal inferiorly displaced position.<sup>[1]</sup> It may cover a significant portion of the cornea and pupillary aperture so as to cause visual impairment. Congenital blepharoptosis results from a developmental dystrophy of the levator muscle of unknown aetiology. It may be associated with third nerve misdirection, Marcus-Gunn jaw-winking phenomenon or blepharophimosis syndrome.<sup>[1]</sup> Ptosis is usually graded as mild (up to 2 mm), moderate (3 mm) and severe (4 mm or more). In myogenic ptosis, there is either absence of levator function or the levator function is poor i.e. less than 4mm. In these patients, the diagnosis is established

if there is failure of the upper lid to descend to the level of lower limbus in down gaze. In cases where the levator function is absent or is less than 4 mm, the most effective surgical approach is suspension of the upper lid to the frontalis muscle. In this way, the upper lid is elevated on raising the brows. Normally the upper lid margin rests about 2 mm below the upper limbus. Abnormal head posturing develops in bilateral cases and it can cause deprivation amblyopia, especially in unilateral cases. Congenital ptosis may, therefore, have a negative effect on the psychological development of the child. The ideal surgical treatment and age of intervention were controversial in the management of congenital ptosis, however congenital ptosis should be corrected in the early years of childhood, and amblyopia treatment

commenced as soon as the diagnosis is established.<sup>[1]</sup>

Various materials including fascia lata<sup>[2,3]</sup>, Palmaris tendon<sup>[4]</sup>, deep temporal fascial graft<sup>[5]</sup>, Mersilene<sup>[6,7]</sup>, Gortex<sup>[8]</sup>, silicone rods<sup>[9-11]</sup> and different sutures<sup>[12]</sup> have been used to fashion the frontalis sling. Recently frontalis muscle advancement<sup>[13]</sup> has been used to bypass the sling. The technique for making a sling has also been quite varied. Some people use a lid crease incision with tarsal fixation of the fascia lata compared to others who use supralash stab incisions to pass the fascia lata beneath the orbicularis without anchorage.<sup>[14]</sup> Fox pentagon<sup>[15]</sup> or Crawford double triangle<sup>[16]</sup> are the two different methods of passing the fascia lata. Cosmetic issues that are raised with standard frontalis suspension surgery include scarring in young children, unsatisfactory geometric tenting of the pretarsal and pre-septal skin, obliteration of the eyelid crease and a poor tarso-corneal interface noted with brow elevation and depression. These may be related to the choice of sling material and to the superficial location of the sling in the eyelid.<sup>[17]</sup> Despite these drawbacks, all surgeons agree that the most successful material is autogenous fascia lata, and this technique has the lowest complication rate.<sup>[18]</sup> Fascia lata mostly completes its development in the first year of life.<sup>[19]</sup> When the length of the upper leg is approximately 20 cm, the length of the fascia lata is sufficient for frontalis suspension.

## Materials and Methods

This study was conducted at GMC Srinagar, India from 1<sup>st</sup> January 2010 to 1<sup>st</sup> March 2012. Thirty patients, 14 females and 16 males of age ranging from 5 to 55 years, having congenital ptosis were included in the study. A detailed history and examination was performed. History included the age of onset of ptosis, its duration, reviewing old photographs (if the history is ambiguous), diplopia symptoms, variability of ptosis during the day and excessive fatigue. A complete examination including cyclorefraction, best corrected visual acuity, biomicroscopic evaluation of the lacrimal meniscus, extraocular movements, pupillary reactions and corneal sensation was performed. Ptosis examination included: lid fissure height, eyelid crease height, upper lid margin to reflex distance (MRD), scleral show, levator function, lagophthalmos, jaw winking and Bell's phenomenon (4+ implies complete disappearance of the cornea and zero corresponds to absence of Bell's phenomenon), inspection for abnormal head posture (e.g. chin elevation) and frontalis contraction. Informed consent

was taken and patients were randomly divided into 2 groups I and II. Group I patients underwent frontalis sling suspension with autologous fascia lata while Group II patients underwent frontalis sling suspension with silicone sling. Difficulty in assessment of pre and post-operative measurements and inadequate length of fascia lata were the reasons for excluding children less than 5 years. Autogenous fascia lata was harvested in all patients using a fascia stripper through a 2.5 cm incision. In both the groups, frontalis brow suspension was performed by employing the modified Fox technique. Stab incisions were made in the lid approximately 2 mm from the lid margin to avoid the lash roots and are made just lateral to the upper punctum and approximately 3 mm from the lateral canthus. Brow incisions were made at a position in line with the medial and lateral canthi. The superior incision was made directly above the mid position of the lid at a distance from the brow incisions to form an equilateral triangle. A Wright fascia needle was used to thread the fascia lata sling through the incisions in such a way so as to have each end exit through the superior incision, while as silicone sling came with a pre attached needle. Care was taken not to enlarge the stab incisions as the sling material was pulled through. The superior incision was undermined to accommodate the knot. Final lid height was determined by tightening the sling till the lid margin just lifts off the cornea. Vicryl 6/0 was used to reinforce the knot. Incisions were closed with vicryl 6/0. A frost was applied for 48 hrs.

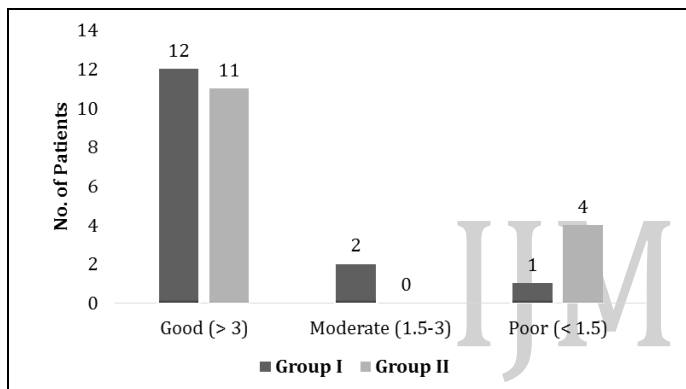
Exclusion criteria included weak Bell's phenomenon (less than 50% of normal), positive phenylephrine test, jaw winking phenomenon, blepharophimosis syndrome, systemic or myopathic disorders with secondary ptosis such as myotonic dystrophy, myasthenia gravis, chronic progressive external ophthalmoplegia, and Graves' disease, history of intra or extra ocular and eyelid surgery, sharp or blunt trauma to the eyelids, eyelid tumors and scars and patients with vertical squint.

## Results

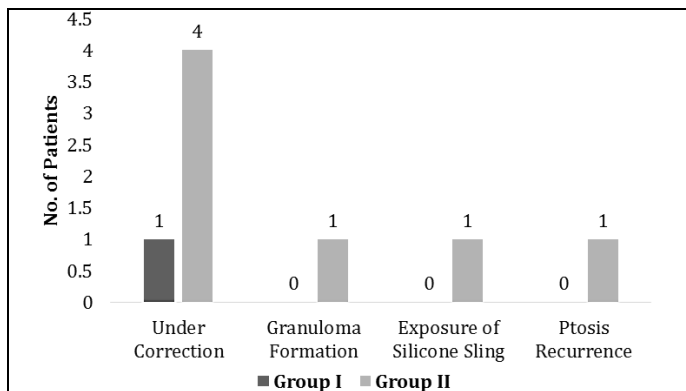
In both the groups, results were assessed at 4 weeks, 8 weeks and at 3 months. All the calculations were based on final results at 3 months. Functional improvement was judged on the basis of post-operative improvement in margin to reflex distance (MRD). MRD of > 3 mm was graded as satisfactory, whereas MRD of < 1.5 mm was considered poor. Satisfactory improvement in MRD was further graded as good (MRD > 3 mm) or moderate (> 2 mm < 3 mm).

Average post-operative MRD with brow up was  $3.55 \pm 0.73$  mm in group I and  $2.95 \pm 0.17$  mm in group II at 3 months after surgery. In Group I, 14 (93%) out of 15 showed satisfactory cosmetic and functional results. Among these, 12 (80%) patients had good MRD and 2 (13%) patients had moderate MRD. The remaining 1 (7%) of 15 patients had poor MRD. In Group II 11 (73%) out of 15 patients showed satisfactory cosmetic and functional results. The remaining 4 (27%) of 15 patients exhibited poor MRD. Under-correction was seen in 4 (27%) of 15 patients, granuloma formation was seen in 1 (7%) of 15 patient, exposure of silicon tube was seen in 1 (7%) of patient in fourth postoperative week, In 1 (7%) of 15 patient, recurrence of ptosis was seen due to slippage of silicone sling. Figures 1 and 2 summarize the functional results and postoperative complications respectively.

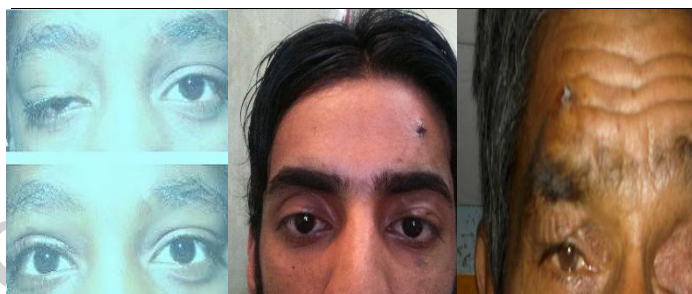
levator function of 5-7 mm, and (3) those with good levator function greater than 8 mm. Although congenital ptosis can be mild and innocuous it often produces functional limitation, changes in the neck and body posture, as well as impact aesthetic and psychological wellbeing of the patient. Frontalis muscle suspension is the gold standard for the treatment of congenital ptosis with poor levator function.<sup>[20]</sup> It creates a linkage between the frontalis muscle and the tarsus of the upper eyelid, which allows for a better eyelid position in primary gaze. Eyelid elevation is then performed with the use of the frontalis muscle. As already mentioned several materials have been used for the purpose but ever since 1966 when Tillet et al reported use of Silicone band No. 40 for frontalis sling suspension surgery the material has been found to have excellent biocompatibility and is being vastly accepted.



**Figure-1: Results of Frontalis Brow Suspension using Fascia Lata (Group I) & Silicone sling (Group II) showing significantly better results in group I than Group II**



**Figure-2: Indicates the post-operative complications encountered in both the groups which have been more in Group II than Group I**



**Figure-3: (1) Photograph 1:** Shows the pre-operative and post-operative photograph of a patient who underwent (right) frontalis brow suspension using autologous fascia lata. Satisfactory cosmetic and functional results were obtained. **(2) Photograph 2:** Shows the post-operative photograph of a patient who underwent successful (left) frontalis brow suspension using silicone sling. **(3) Photograph 3:** Shows resultant exposure of the silicone tube 4 weeks post-operatively in another patient.

However autologous fascia lata has proven to be the method of choice in sling surgery for ptosis.<sup>[21,22]</sup> Wagner, reported neither infection nor granuloma formation with banked fascia lata, however, the observed recurrence rate was 8.3%.<sup>[23]</sup> Silicone frontalis sling requires small skin incision, less surgical time and it can be performed in all eyes with ptosis with poor levator function. Grover et al in 2005 highlighted the complications of harvesting fascia lata including an unsightly scar in the thigh region, hematoma formation, keloid formation and herniation of muscle belly.<sup>[24]</sup> But in the present study no such complications were encountered. Moreover, a scar in the thigh area was not considered as an aesthetic blemish by the patients most probably because of cultural values. Literature review revealed that under-correction is more common in the treatment of congenital ptosis and the rate varies from 5-35% depending on the series. As pointed out, 1 patient in

**Discussion**

The surgical approach to congenital ptosis is generally based on the amount of levator function. Patients with congenital ptosis have been grossly divided into three groups based on the levator function: (1) those with poor levator function of 4 mm or less, (2) those with fair

this group developed granuloma on 6th post-operative week which was later excised. Various studies reported that complication rate of granuloma formation varies from 3-7%.<sup>[25]</sup> Our results also match with the results demonstrated by Munira et al<sup>[26]</sup> as well as Usha et al reported one recurrence of ptosis due to slippage of silicone sling over the tarsus<sup>[27]</sup>, while in the current study, we also encountered one recurrence of ptosis due to same reason.

## Conclusion

Blepharoptosis surgery is one of the most common oculoplastic procedures; the aim of which is to clear the visual axis, reducing amblyopia in young patients and improving superior visual fields in adult patients. The secondary goal is to improve appearance by producing symmetric lid crease and contour in the upper lids. The visual impact of ptosis can be significant for the patient. The negative psychosocial impact of an abnormal eyelid position should not be discounted especially in young children and teenagers. Recent studies have identified a 3-10% incidence of amblyopia with severe congenital ptosis. We obtained clinically significant functional and cosmetic improvement with lower complication rates in patients in whom frontalis sling procedure was performed using fascia lata (93%) as compared to patients in whom silicone sling was used (73%). Large scale prospective studies are needed to evaluate the true outcome of different materials and sling designs in frontalis suspension surgery.

## References

1. Oral Y, Ozgur OR, Akcay L, Ozbas M, Dogan OK. Congenital ptosis and Amblyopia. *J Pediatric Ophthalmol Strabismus* 2010;47:101-4.
2. Broughton WL, Matthews JG 2nd, Harris DJ Jr. Congenital ptosis. Results of treatment using lyophilized fascia lata for frontalis suspensions. *Ophthalmology* 1982;89:1261-6.
3. Esmaili B, Chung H, Pashby RC. Long-term results of frontalis suspension using irradiated, banked fascia lata. *Ophthalm Plast Reconstr Surg* 1998;14:159-63.
4. Wong CY, Fan DS, Ng JS, Goh TYH, Lam DSC. Long-term results of autogenous palmaris longus frontalis sling in children with congenital ptosis. *Eye* 2005;19:546-8.
5. Tellioglu AT, Saray A, Ergin A. Frontalis sling operation with deep temporal fascial graft in blepharoptosis repair. *Plast Reconstr Surg* 2002;109:243-8.
6. Zafar Ullah M, Sahi T, Tayyab AA. Merselene mesh use as a frontalis sling in ptosis surgery. *Pakistan J Med Res* 2003;42:126-8.
7. Mehta P, Patel P, Olver JM. Functional results and complications of Mersilene mesh use for frontalis suspension ptosis surgery. *Br J Ophthalmol* 2004;88:361-4.
8. Steinkogler FJ, Kuchar A, Huber E, Arockar-Mettinger E. Gore-Tex

- soft-tissue patch frontalis suspension technique in congenital ptosis and in blepharophimosis-ptosis syndrome. *Plast Reconstr Surg* 1993;92:1057-60.
9. Hussain MM. Correction of Congenital Ptosis using Silicone Material For Frontalis suspension. *Pak J Ophthalmol* 1995;11:115-7.
10. Carter SR, Meecham WJ, Seiff SR. Silicone frontalis slings for the correction of blepharoptosis: indications and efficacy. *Ophthalmology* 1996;103:623-30.
11. Bernardini FP, de Conciliis C, Devoto MH. Frontalis suspension sling using a silicone rod in patients affected by myogenic blepharoptosis. *Orbit*. 2002; 21: 195-8.
12. Liu D. Blepharoptosis correction with frontalis suspension using a supramid sling: duration of effect. *Am J Ophthalmol*. 1999; 128: 772-3.
13. Ramirez OM, Pena G. Frontalis muscle advancement: a dynamic structure for the treatment of severe congenital eyelid ptosis. *Plast Reconstr Surg* 2004;113:1841-9.
14. Yagci A, Egrilmez S. Comparison of cosmetic results in frontalis sling operations: the eyelid crease incision versus the supralash stab incision. *J Pediatr Ophthalmol Strabismus*. 2003;40:213-6.
15. Fox SA. Correction of ptosis. *New Orleans Academy of Ophthalmology Symposium on surgery of the ocular adnexa*. St. Louis: The CV Mosby Co. 1966.
16. Crawford JS. Use of fascia lata in the correction of ptosis. *Adv Ophthalmic Plastic Reconstr Surg*. 1982;1:221.
17. Wasserman BN, Sprunger DT, Helveston EM. Comparison of materials used in frontalis suspension. *Arch Ophthalmol* 2001;119:687-91.
18. Ben Simon GJ, Macedo AA, Schwarcz RM, Wang DY, McCann JD, Goldberg RA. Frontalis suspension for upper eyelid ptosis: evaluation of different surgical designs and suture material. *Am J Ophthalmol* 2005;140:877-85.
19. Eyelid. In: Standring S, editor. *Gray's anatomy: the anatomical basis of clinical practice*. London: Churchill Livingstone; 2004. p. 437-520.
20. Clauser L, Tieghi R, Galiè M. Palpebral ptosis: clinical classification, differential diagnosis, and surgical guidelines: an overview. *J Craniofac Surg* 2006;17:246-54.
21. Lee MJ, Oh JY, Choung HK, Kim NJ, Sung MS, Khwang SI. Frontalis sling operation using silicone rod compared with preserved fascia lata for congenital ptosis a three-year follow-up study. *Ophthalmology* 2009;116:123-9.
22. Leibovitch I, Leibovitch L, Dray JP. Long-term results of frontalis suspension using autogenous fascia lata for congenital ptosis in children under 3 years of age. *Am J Ophthalmol* 2003;136:866-71.
23. Wagner RS, Mauriello JA Jr, Nelson LB, Calhoun JH, Flanagan JC, Harley RD. Treatment of congenital ptosis with frontalis suspension: a comparison of suspensory materials. *Ophthalmology* 1984;91:245-8.
24. Grover AK, Malik S, Choudhury Z. Recent advances in lid, orbital and lacrimal surgery. In: Condon PI, Garg A, Pandey SK, Chang DF, Papadopoulos PA, Maloof AJ, editors. *Advances in ophthalmology*. New Delhi: Anshan Ltd; 2005. p. 713-24.
25. McCulley TJ, Kersten RC, Kulwin DR, Feuer WJ. Outcome and influencing factors of external levator palpebrae superioris aponeurosis advancement for blepharoptosis. *Ophthalm Plast Reconstr Surg* 2003;19:388-93.
26. Shakir M, Zafar S, Bokhari SA, Kamil Z. To Compare the Results of Frontalis Brow Suspension using Fascia Lata & Silicone Tube. *Ophthalmology Update* 2011;9.
27. Usha R, Dudeja G. Evaluation of frontalis sling surgery using silicone rod for correction of blepharoptosis in Indian population in a tertiary eye care centre. 2009. Available from: URL: <http://www.aios.org/proceed09/paper2009/ORBIT-II/ORBIT-II3.pdf>.

**Cite this article as:** Khan A, Majid O, Wani J. Fascia lata versus silicone sling frontalis suspension for correction of congenital blepharoptosis. *Int J Med Sci Public Health* 2014;3:700-703.

**Source of Support:** Nil

**Conflict of interest:** None declared